OPEN

Anatomy of the Superficial Fascia System of the Breast: A Comprehensive Theory of Breast Fascial Anatomy

Robert D. Rehnke, M.D.
Rachel M. Groening, M.S.
Eric R. Van Buskirk, M.D.
John M. Clarke, M.D.

St. Petersburg and Bradenton, Fla.; and Lynchburg, Va.

Background: It has been two centuries since Petrus Camper identified superficial fascia and over 175 years since Sir Astley Cooper wrote his book on the anatomy of the breast. In the 1990s, Ted Lockwood taught us the importance of the superficial fascia layers in body contouring procedures he pioneered. These descriptions, however, fail to explain the three-dimensional fascial system in the breast. The authors set out to discover and describe a theory of superficial fascia structures responsible for breast shape.
Methods: The nature of the superficial fascia system that surrounds the breast and its attachments to the chest were studied in 12 cadaver breast dissections and in clinical cases of both cosmetic and reconstructive breast procedures.
Results: The authors found a three-dimensional, closed system of fascia and fat surrounding the corpus mammae, which attaches to the skin by means of specialized vertical cutaneous ligaments, or Cooper ligaments, and which attaches to the chest wall by means of a three-dimensional zone of adherence at the breast's periphery.
Conclusions: The breast is shaped by a three-dimensional, fibrofatty fascial system. Two layers of this system surround the corpus mammae and fuse together around it, and anchor it to the chest wall in a structure we have called the circummammary ligament. (*Plast. Reconstr. Surg.* 142: 1135, 2018.)

The first reports of superficial fascia began in the early nineteenth century with the description by Scarpa and Camper of layers of fascia and fat between the muscle and skin. In 1840, Sir Astley Cooper published his book, *On the Anatomy of the Breast.*[1] Cooper wrote, concerning the fascia mammae, that it contained two layers, one anterior to the breast gland and one posterior to it. He described "ligamenta suspensoria," which connected to the skin and muscle. On the anterior surface of the breast, these ligaments, "form little petals, like a blooming rose, turned forwards to the skin, in the depressions between them the fat is lodged." On the borders of the breast he said, "[The] clavicular and sternal margin makes smooth radii, but the axillary and abdominal margin turns upon itself and forms a hem."

In another passage from his book he states, "In a large and fat person, the breast is far removed from the skin, and from the pectoralis major muscle, by the immense quantity of adipose matter placed before and behind the gland, and in the intervening structures." These "intervening structures" were further described: "The fat is also

From plastic surgery private practice; OMS-II, Lake Erie College of Osteopathic Medicine; general surgery private practice; and general medicine private practice.
Received for publication August 2, 2017; accepted May 2, 2018.
Copyright © 2018 The Authors. Published by Wolters Kluwer Health, Inc. on behalf of the American Society of Plastic Surgeons. All rights reserved. This is an open-access article distributed under the terms of the Creative Commons Attribution-Non Commercial-No Derivatives License 4.0 (CCBY-NC-ND), where it is permissible to download and share the work provided it is properly cited. The work cannot be changed in any way or used commercially without permission from the journal.
DOI: 10.1097/PRS.0000000000004948

Disclosure: *The authors have no financial interest to declare in relation to the content of this article.*

Supplemental digital content is available for this article. Direct URL citations appear in the text; simply type the URL address into any Web browser to access this content. Clickable links to the material are provided in the HTML text of this article on the *Journal*'s website (www.PRSJournal.com).

deposited behind the breast, in the posterior layer of fascia, and in the ligamentous or fascial loops which connect the breast to the aponeurosis of the pectoralis major muscle."

This concept of superficial fascia fusing with deep structures is not new in other anatomical regions, such as the face and neck. Stuzin et al. described zones of adherence in the face, between the superficial musculoaponeurotic system (SMAS) and deep fascia and periosteum, in the justification of the face lift techniques popularized in the 1990s.[2] More recently, Pessa[3] published his research on facial anatomy and concluded: "SMAS fusion zones exist as bi-laminar membranes, travel from the deep to superficial fascia, and determine the anatomic boundaries of the fat compartments and anatomic spaces." Elsewhere, he states that these zones of adherence are the location of nerves, blood vessels, and lymphatics, which travel from deep to superficial planes into the SMAS fat and mimetic muscles.[4] The zones of adherence thus prevent shearing of these structures with movement.

The final clue to the superficial fascia system of the breast, and its relation to the underlying chest wall, comes from an article published in 2001, by Rohrich et al.,[5] which described five "zones of adherence" between superficial fascia and underlying deep fascia of the thigh and buttocks. They state that the superficial fascia system, with its anchorage to deep fascia, shapes the soft tissue into buttocks, hips, saddlebag areas, and upper medial thigh fat pad. These discoveries laid a foundation for a comprehensive understanding of the superficial fascia system of the breast. This article attempts to connect the dots, so to speak, for the reader and expose the three-dimensional fascial network that encases, shapes, and supports the breast.

METHODS

This study began in July of 1994 while two of us (R.D.R. and E.V.B.) were still in plastic surgery residency. We dissected 12 fresh cadaver breast specimens in six female cadavers, between July of 1994 and June of 1995. These dissections were performed using manta ray–shaped balloon dissectors for a blunt dissection of the subglandular and submuscular spaces. Balloons were filled to volumes exceeding 1000 cc, and careful removal of surrounding skin was then performed to observe the fascial boundaries of the dissection. To ensure that this finding was not an artifact, we made clinical observations covering more than 20 years of clinical practice, focused on breast surgery. When possible, video recording of cosmetic and reconstructive breast procedures were made and studied. This study does not violate the Declaration of Helsinki; there was no testing or manipulation of the patient's standard of care. This observational study respected the rights of the patients and obtained informed consent for all of the videos and photographs used.

RESULTS

In the fresh cadaver laboratory, we inflated a manta ray–shaped balloon dissector placed in the subglandular space and found a ring of connective tissue limiting the dissection. Careful removal of the skin demonstrated a somewhat circular ring of fusion between superficial fascia layers and the deep fascia of the chest wall. (**See Video Supplemental Digital Content 1**, which shows part 1 of a fresh cadaver dissection, in 1995, of the circummammary ligament, using GSI 1200-cc balloon dissection. This video shows subglandular and submuscular blunt dissection, available in the "Related Videos" section of the full-text article on PRSJournal.com or, for Ovid users, available at ***http://links.lww.com/PRS/D14***. **See Video, Supplemental Digital Content 2**, which demonstrates part 2 of the cadaver dissection of the circummammary ligament, summarizing the findings of a blunt balloon dissection demonstrating a zone of fusion, between superficial and deep fascia of the chest, available in the "Related Videos" section of the full-text article on PRSJournal.com or, for Ovid users, available at ***http://links.lww.com/PRS/D15***.) In each dissection, a continuous circumferential zone of fascial adhesion was found between the superficial fascia and deep fascia of the chest wall, which defined the boundary of the breast. Inferiorly, the medial aspect originates on the lateral sternum opposite the fourth costal cartilage. The inferior and inferolateral portions are attached to the chest between the fifth rib and the sixth costal interspace, in the region between the pectoralis major muscle and the rectus abdominis. The lateral aspect runs lateral to the pectoralis major, over the serratus anterior muscle. As the circle continues superiorly, the zone of adhesion attaches to the clavipectoral fascia, on its way to the superior boundary at the deep fascial division of the clavicular and sternocostal head of the pectoralis major. The circle is completed medially along the sternal adhesions.

Clinical observations have shown that there are two layers of superficial fascia that surround the breast. The corpus mammae in the center is

Video 1. Supplemental Digital Content 1 shows part 1 of a fresh cadaver dissection, in 1995, of the circummammary ligament, using GSI 1200-cc balloon dissection. This video shows subglandular and submuscular blunt dissection, available in the "Related Videos" section of the full-text article on PRSJournal.com or, for Ovid users, available at ***http://links.lww.com/PRS/D14***.

Video 2. Supplemental Digital Content 2 demonstrates part 2 of the cadaver dissection of the circummammary ligament, summarizing the findings of a blunt balloon dissection demonstrating a zone of fusion, between superficial and deep fascia of the chest, available in the "Related Videos" section of the full-text article on PRSJournal.com or, for Ovid users, available at ***http://links.lww.com/PRS/D15***.

surrounded by a layer of fat on both the superficial and deep surface (Fig. 1). Beginning at the breast surface, and dissecting from superficial to deep, one encounters a 2- to 3-mm layer of subcutaneous fat underneath the dermis. Next is the more superficial layer of the two layers of superficial fascia: the anterior lamellar fascia (an analogue to the Camper fascia, in the groin). Just deep to this is a roughly 10-mm layer of fat, the anterior lamella fat, which covers the anterior surface of the corpus mammae (the capsule of the corpus is actually a pseudo capsule, as there is no epithelium on its surface; instead, it is made of compression of the surrounding fascia as the corpus expands with development at puberty). Deep to the corpus mammae, another layer of fat, the posterior lamella fat, is encountered. Underneath it all is the posterior lamella fascia (an analogue to the Scarpa fascia, in the groin) (Fig. 2). (**See Video, Supplemental Digital Content 3**, which demonstrates superior pedicle breast reduction, illustrating the anterior and posterior lamella of the superficial fascia system of the breast, available in the "Related Videos" section of the full-text article

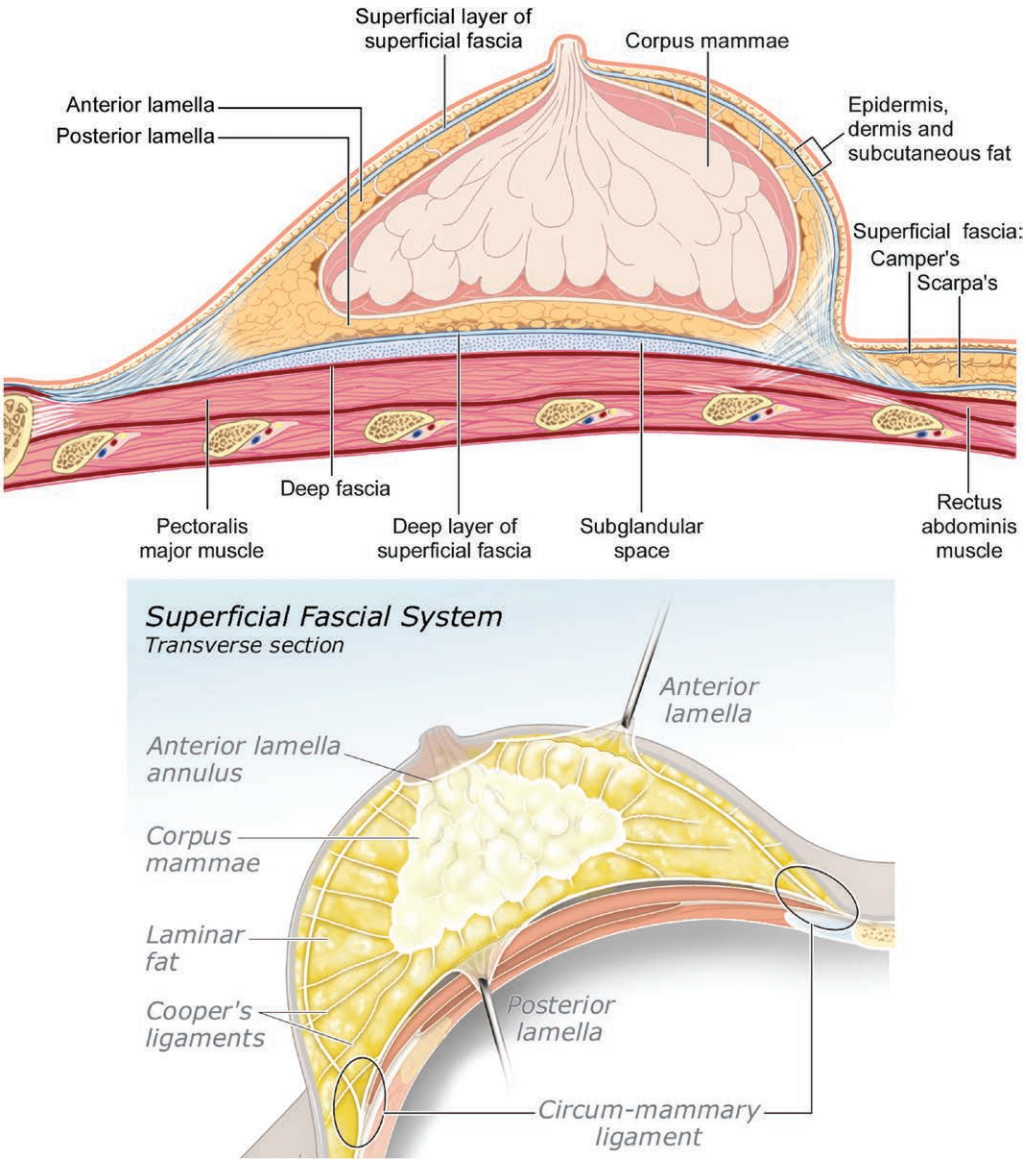

Fig. 1. (*Above*) Superficial fascial system; sagittal view. The corpus mammae is bounded by two layers of fascia and fat, the anterior and posterior lamina. (Used with permission by Susan Gilbert.) (*Below*) Superficial fascial system; transverse section. The anterior and posterior lamina connect to the deep fascia of the chest wall in a circular zone of adhesion called the circummammary ligament, which connects the breast to the chest, providing support and structure to the breast. (Used with permission by Susan Gilbert.)

on PRSJournal.com or, for Ovid users, available at ***http://links.lww.com/PRS/D16***.) The deeper posterior lamella fascia is several times thicker than the nearly nonexistent anterior lamella superficial fascia. However, the anterior lamina fat layer is two to three times thicker than the posterior lamella fat (Fig. 2). A fusion between the anterior lamella and posterior lamella of superficial fascia surrounding the breast, and the deep fascia of the chest, is called the "circummammary ligament" (Fig. 3). (**See Video, Supplemental Digital Content 4**, which demonstrates breast reduction, showing the superior portion of the circummammary ligament, available in the "Related Videos" section of the full-text article on PRSJournal.com or, for Ovid users, available at ***http://links.lww.com/PRS/D17***. **See Video, Supplemental Digital Content 5**, which demonstrates breast reduction, showing the inframammary fold portion of the circummammary ligament, available in the "Related Videos" section of the full-text article on PRSJournal.com or, for Ovid users, available

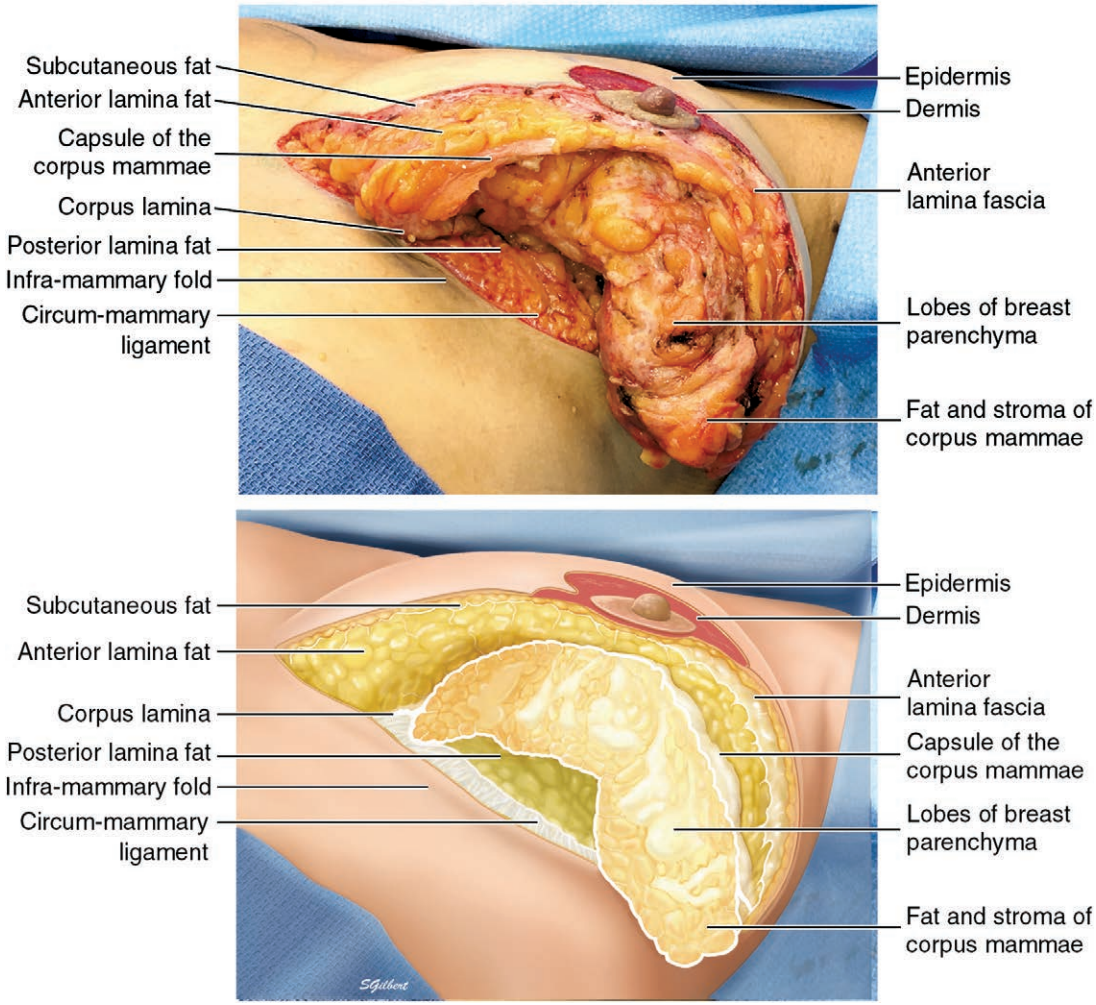

Fig. 2. (*Above*) Inferior view of the breast and superficial fascial system during a superior pedicle breast reduction. (Used with permission by Susan Gilbert.) (*Below*) Illustration of the breast and superficial fascial system during a superior pedicle breast reduction. (Used with permission by Susan Gilbert.)

Video 3. Supplemental Digital Content 3 demonstrates superior pedicle breast reduction, illustrating the anterior and posterior lamella of the superficial fascia system of the breast, available in the "Related Videos" section of the full-text article on PRSJournal.com or, for Ovid users, available at ***http://links.lww.com/PRS/D16***.

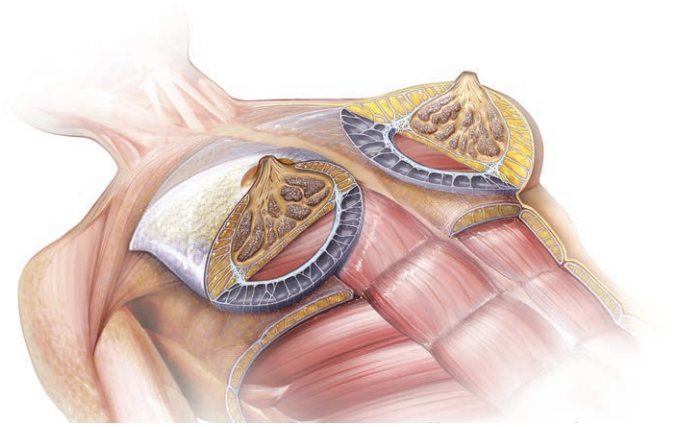

Fig. 3. Superficial fascial system; anterior and posterior lamina surround the corpus mammae, which can be seen erupting through an opening in the anterior lamina fat, the anterior lamina annulus. Also, note that the inframammary fold portion of the circummammary ligament lies over the inscription between the rectus abdominis and pectoralis major muscle. (Used with permission by Illumination Studios.)

Video 4. Supplemental Digital Content 4 demonstrates breast reduction, showing the superior portion of the circummammary ligament, available in the "Related Videos" section of the full-text article on PRSJournal.com or, for Ovid users, available at ***http://links.lww.com/PRS/D17***.

Video 5. Supplemental Digital Content 5 demonstrates breast reduction, showing the inframammary fold portion of the circummammary ligament, available in the "Related Videos" section of the full-text article on PRSJournal.com or, for Ovid users, available at ***http://links.lww.com/PRS/D18***.

at ***http://links.lww.com/PRS/D18***. **See Video, Supplemental Digital Content 6**, which demonstrates breast reduction, showing the lateral portion of the circummammary ligament, available in the "Related Videos" section of the full-text article on PRSJournal.com or, for Ovid users, available at ***http://links.lww.com/PRS/D19***. **See Video, Supplemental Digital Content 7**, which demonstrates breast reduction, showing the medial portion of the circummammary ligament, available in the "Related Videos" section of the full-text article on PRSJournal.com or, for Ovid users, available at ***http://links.lww.com/PRS/D20***.) Modified vertical cutaneous ligaments, the Cooper ligaments, run from the posterior lamina fascia up through the corpus, penetrating the anterior lamina fat and fascia, on their way to the dermis. The corpus mammae penetrates the anterior lamina through an opening, in the anterior lamina fat and fascia beneath the areola, we call the anterior lamina annulus. This means there is no subcutaneous fat or anterior lamina fat between the dermis of the areola and the corpus mammae (Fig. 3). (**See Video, Supplemental Digital Content 8**, which

Video 6. Supplemental Digital Content 6 demonstrates breast reduction, showing the lateral portion of the circummammary ligament, available in the "Related Videos" section of the full-text article on PRSJournal.com or, for Ovid users, available at ***http://links.lww.com/PRS/D19***.

Video 7. Supplemental Digital Content 7 demonstrates breast reduction, showing the medial portion of the circummammary ligament, available in the "Related Videos" section of the full-text article on PRSJournal.com or, for Ovid users, available at ***http://links.lww.com/PRS/D20***.

demonstrates small breast reduction, illustrating the anterior lamella annulus, available in the "Related Videos" section of the full-text article on PRSJournal.com or, for Ovid users, available at ***http://links.lww.com/PRS/D21***.)

The circummammary ligament surrounds the breast and defines its perimeter. The circummammary ligament is a three-dimensional, roughly circular structure composed of superficial fascia collagen fibers that encase a ring of fat and attach it to the deep fascia of the chest, as a circular zone of adherence (**see Video, Supplemental Digital Content 4,** ***http://links.lww.com/PRS/D17***). The circummammary ligament is consistently found in every patient, but varies in characteristics depending on the body habitus of the person. People with more body fat have larger lobules of fat between the fibers of collagen and therefore a larger ring of attachment. This ring of fascia and fat that composes the circummammary ligament varies in thickness, depending on what part of the circle one is looking at. Inferiorly is the inframammary ligament portion which is strong, thick, and wide in patients with more body fat. The sternal portion lacks the fat seen inferiorly, so it is more narrow in comparison. It has a high density of collagen fibers attaching to the deep fascia covering the parasternal area and therefore is the zone with the strongest anchorage. Laterally, the circummammary ligament collagen and fat are less dense and cover a larger area. Superiorly, the circummammary ligament is very thin and contains virtually no fat and therefore is difficult to see. It runs between the clavicular head of the pectoralis major and its sternocostal head (**see Video, Supplemental Digital Content 5,** ***http://links.lww.com/PRS/D18***). The fascial cleft under the breast and within the confines of the circummammary ligament is known as the "subglandular" space, and is filled with loose areolar connective tissue. The circummammary ligament fuses to the deep fascia covering the chest wall and anchors the breast in place; the subglandular space allows for breast movement and prevents its attachment from being rigid.

Video 8. Supplemental Digital Content 8 demonstrates small breast reduction, illustrating the anterior lamella annulus, available in the "Related Videos" section of the full-text article on PRSJournal.com or, for Ovid users, available at ***http://links.lww.com/PRS/D21***.

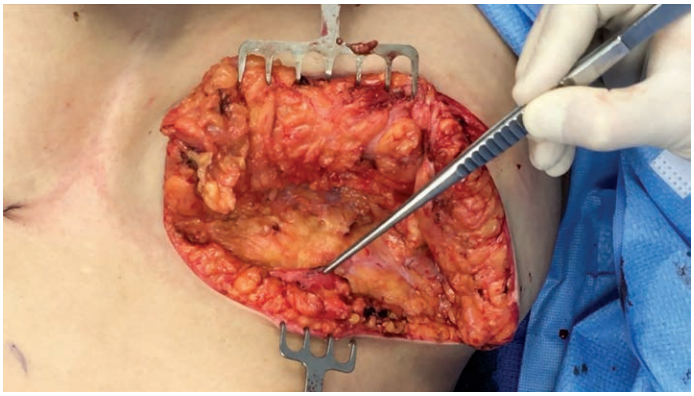

Fig. 4. Corpus lamina. The corpus lamina is a layer of fascia separating the anterior and posterior lamina, and is the layer of fascia that the corpus mammae develops in. Inferior to the corpus, at the inframammary fold, it can be seen as a layer of fascia (being held up with forceps).

The corpus mammae is itself in a fascial layer that separates the anterior and posterior lamina fat, and is referred to as the corpus lamina (Fig. 4). (**See Video, Supplemental Digital Content 9**, which demonstrates breast reduction, showing the corpus lamina at the inframammary fold, available in the "Related Videos" section of the full-text article on PRSJournal.com or, for Ovid users, available at ***http://links.lww.com/PRS/D22***.) The entire structure of fat and fascia, surrounding the corpus mammae, is the superficial fascia system, which is responsible for the shape of the breast and thus is the key to breast aesthetics.

The circummammary ligament provides a fixed passage for nerves, lymphatics, and large-caliber blood vessels. Just as it is in the face, the zone of adherence surrounding the breast is the channel that blood vessels and nerves travel through on their way to the breast. The major arterial supply comes from the chest wall and travels through the collagen fibers of the circummammary ligament before entering the breast (Figs. 5 and 6).

Video 9. Supplemental Digital Content 9 demonstrates breast reduction, showing the corpus lamina at the inframammary fold, available in the "Related Videos" section of the full-text article on PRSJournal.com or, for Ovid users, available at ***http://links.lww.com/PRS/D22***.

DISCUSSION

Controversy exists over the superficial fascia of the breast and the nature of the anatomy of the inframammary fold. Much has been written in the past 200 years concerning the superficial fascia and inframammary fold, with major disagreement over whether or not it should be considered a ligament or not.[6–8] There is also disagreement in the literature over the existence of one or two layers of superficial fascia in the breast region of the chest.[9] Haagenson, in his book *Diseases of the*

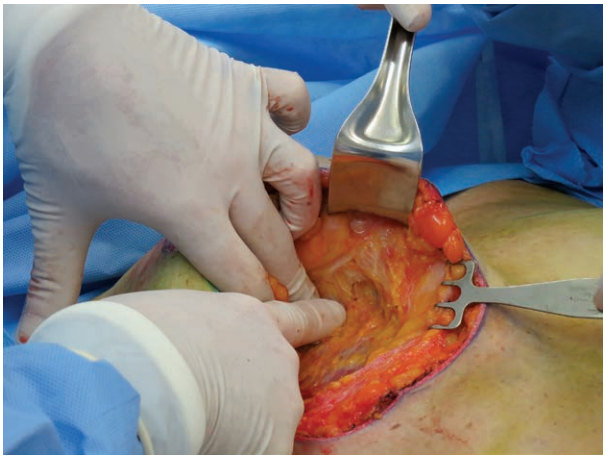

Fig. 5. Medial circummammary ligament carrying perforating segmental vessels, nerves, and lymphatics.

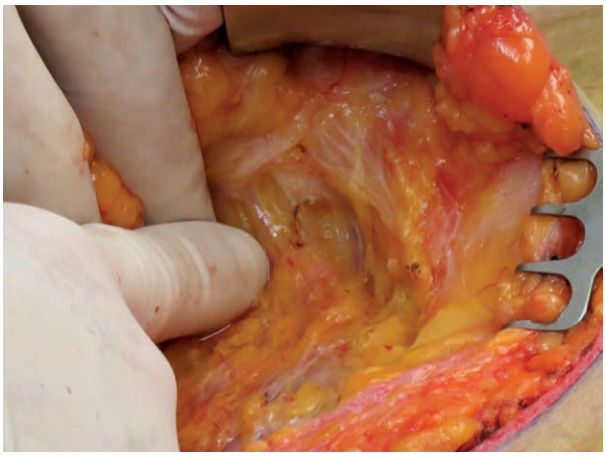

Fig. 6. Medial circummammary ligament carrying vessels, nerves, and lymphatics (higher magnification).

Breast,[10] states: "The superficial layer of this fascia is a very delicate but definite structure which will be seen only by the surgeon who looks sharply for it and who keeps the operative field dry enough to permit its identification. The anatomist in his dissecting room is usually unable to identify it." We have used tumescent anesthesia, injected both in the subglandular space and subcutaneously, to achieve the bloodless field required to find this layer throughout the breast. The only part of the breast where it is absent is the anterior lamina annulus.

Cooper is credited with the discovery of the suspensory ligaments of the breast that bear his name[1]; however, Brinkman and Hage rightly point out that Andreas Vesalius described the superficial fascia of the breast, which he called "the fleshy membrane," in 1543.[11] Vesalius understood that the superficial fascia system of the breast was a special modification of a system found throughout the entire body.[12] In the 1990s, Ted Lockwood led the way in establishing the importance of the superficial fascia in breast and body contouring.[13,14] Many others have laid the groundwork for describing the superficial fascia as a continuous organ between the skin and deep fascia.[15,16] Rohrich et al. described zones of adherence between the superficial fascia and the deep fascia and their role in shaping the soft tissues.[5] We observed a similar zone of adherence surrounding the breast and anchoring it to the chest, which we named the circummammary ligament. Studies performed by Würinger et al.[17] and Matousek et al.[18] come very close to describing the superficial fascia system of the breast, but miss the three-dimensional "big picture." They state that the literature is full of conflicting results concerning the ligamentous anatomy of the breast, because of various dissection techniques causing artifacts. We agree, and feel their use of frozen sagittal and horizontal cadaver sections makes it difficult to visualize the delicate three-dimensional network of the superficial fascia system. We are in agreement about the existence of a fascial ring around the breast, which the neurovascular supply to the breast crosses. Matousek et al., however, focus on seven separate ligamentous structures; they fail to see that the ring of attachment is continuous with an entire three-dimensional system of fascia and fat.

Würinger et al. commit the same error, seeing the breast supported by three ligaments forming a suspensory sling, which their dissection technique artificially creates by dividing the circummammary ligament and ignoring the connective tissue adherence of the superior breast. Furthermore, their anatomical studies were on postmenopausal female cadavers in their seventies and eighties. These specimens undoubtedly had parenchymal involution and fatty replacement, and ptosis and connective tissue decline. They may have mistaken an atrophic anteroinferior capsule of the corpus mammae for a septum. In a fatty depleted, postmenopausal breast, this could seem to divide the breast gland into a superior two-thirds and an inferior third. In obese patients with large breasts, the anterior lamella fat below could be confused for additional breast tissue. Studies by Carlson et al. in the mid 1990s showed less than 0.02 percent of breast glandular tissue present in this region.[19] We believe Würinger et al. found a portion of the "ligamentous suspension of the mammary gland," that does not travel through the gland, but instead underneath it.

This vision of breast anatomy, supported by our videos, fits into the greater scheme of anatomical order seen in the rest of the body. It suggests opportunity for further study of the ontology of the breast, and the dynamic forces that change the shape of the breast throughout life.

CONCLUSIONS

The system of fascia that surrounds the corpus mammae, and encases it in two layers of fat and fascia, is named the superficial fascia system of the breast. Its anchorage to the deep fascia of the chest at the breast's perimeter is the circummammary ligament. The Cooper ligaments, which are specialized vertical cutaneous ligaments, travel from the posterior lamina fascia, through the breast gland and anterior lamina, to anchor in the

skin. The circummammary ligament acts as the passage that arteries and nerves travel through on their way to the breast parenchyma and nipple-areola. The superficial fascia system is responsible for the shape of the breast. Stretching and relaxing of the superficial fascia system, through aging or after surgery, along with variable amounts of support from the underlying chest wall, leads to breast ptosis. An intimate knowledge of this system is foundational to both reconstructive and cosmetic breast surgery.

Robert D. Rehnke, M.D.
6606 10th Avenue N
St. Petersburg, Fla. 33710
robertrehnke@me.com

REFERENCES

1. Cooper AP. *On the Anatomy of the Breast.* London: Longman, Orme, Green, Brown, and Longmans; 1840. Available at: https://jdc.jefferson.edu/cooper/60/. Accessed September 6, 2018.
2. Stuzin JM, Baker TJ, Gordon HL. The relationship of the superficial and deep facial fascias: Relevance to rhytidectomy and aging. *Plast Reconstr Surg.* 1992;89:441–449; discussion 450–451.
3. Pessa JE. SMAS fusion zones determine the subfascial and subcutaneous anatomy of the human face: Fascial spaces, fat compartments, and models of facial aging. *Aesthet Surg J.* 2016;36:515–526.
4. Pessa JE, Kenkel JM, Heldermon CD. Periorbital and temporal anatomy, "targeted fat grafting," and how a novel circulatory system in human peripheral nerves and brain may help avoid nerve injury and blindness during routine facial augmentation. *Aesthet Surg J.* 2017;37:969–973.
5. Rohrich RJ, Smith PD, Marcantonio DR, Henkel JM. The zones of adherence: Role in minimizing and preventing contour deformities in liposuction. *Plast Reconstr Surg.* 2001;107:1562–1569.
6. Bayati S, Seckel BR. Inframammary crease ligament. *Plast Reconstr Surg.* 1995;95:501–508.
7. Muntan CD, Sundine MJ, Rink RD, Acland RD. Inframammary fold: A histologic reappraisal. *Plast Reconstr Surg.* 2000;105:549–556; discussion 557.
8. Garnier D, Antonin R, Foulon P, et al. Le sillon sous-mammaire: mythe ou réalité?. *Ann Chir Plast Esthet.* 1991;36:313–319.
9. Reggio G, Quatrone P, Nava M. Anatomical study of the breast superficial fascia system: The inframammary fold unit. *Eur J Plast Surg.* 2000;23:310–315.
10. Haagenson CD. Anatomy of the mammary gland. In: *Diseases of the Breast.* 2nd ed. Philadelphia: Saunders; 1971:16–17.
11. Brinkman RJ, Hage JJ. Andreas Vesalius' 500th anniversary: First description of the mammary suspensory ligaments. *World J Surg.* 2016;40:2144–2148.
12. Richardson WF, Carman JB. *Andreas Vesalius on the Fabric of the Human Body. Book V: The Organs of Nutrition and Generation.* Novato, Calif: Norman Publishing; 2007.
13. Lockwood T. Reduction mammaplasty and mastopexy with superficial fascial system suspension. *Plast Reconstr Surg.* 1999;103:1411–1420.
14. Lockwood TE. Superficial fascia system (SFS) of the trunk and extremities: A new concept. *Plast Reconstr Surg.* 1991;87:1009–1018.
15. Markman B, Barton FE Jr. Anatomy of the subcutaneous tissue of the trunk and lower extremity. *Plast Reconstr Surg.* 1987;80:248–254.
16. Abu-Hijleh MF, Roshier AL, Al-Shboul Q, Dharap AS, Harris PF. The membranous layer of superficial fascia: Evidence for its widespread distribution in the body. *Surg Radiol Anat.* 2006;28:606–619.
17. Würinger E, Mader N, Posch E, Holle J. Nerve and vessel supplying ligamentous suspension of the mammary gland. *Plast Reconstr Surg.* 1998;101:1486–1493.
18. Matousek SA, Corlett RJ, Ashton MW. Understanding the fascial supporting network of the breast: Key ligamentous structures in breast augmentation and a proposed system of nomenclature. *Plast Reconstr Surg.* 2014;133:273–281.
19. Carlson GW, Grossl N, Lewis MM, Temple JR, Styblo TM. Preservation of the inframammary fold: What are we leaving behind? *Plast Reconstr Surg.* 1996;98:447–450.